

The Tissue-selecting Technique: Segmental Stapled Hemorrhoidopexy

Hong-Cheng Lin, M.D.¹ • Lei Lian, M.D.¹ • Shang-Kui Xie, M.D.¹ • Hui Peng, M.D.¹
Jian-Dong Tai, M.D.² • Dong-Lin Ren, M.D.¹

¹ Department of Coloproctology, the Sixth Affiliated Hospital of Sun Yat-sen University (Gastrointestinal & Anal Hospital), Guangzhou, People's Republic of China

² Department of Colorectal Surgery, the First Affiliated Hospital of Jilin University, Changchun, People's Republic of China

ABSTRACT: We describe a technique for the management of prolapsing hemorrhoids, with the aim to minimize the risk of anal stricture and rectovaginal fistula and to reduce the impact of the stapling technique on rectal compliance. This modified procedure was successfully applied in China, and preliminary data showed promising outcomes (see Video, Supplemental Digital Content 1, <http://links.lww.com/DCR/A117>).

KEY WORDS: Anal stricture; Circular stapled hemorrhoidopexy; Segmental stapled hemorrhoidopexy; Prolapsing hemorrhoids; Rectal compliance; Rectovaginal fistula; Tissue-selecting technique.

Circular stapled hemorrhoidopexy (CSH) has gained recent widespread popularity largely because of its more minimally invasive nature coupled with favorable reports of functional outcomes.^{1,2} However, with the broader adoption of CSH over the past 14 years, there have been reports of moderately severe complications including anal stricture, defecatory dysfunction, and rectovaginal fistula (RVF). In this respect, the incidence of stricture following CSH has been reported to be as high as 22%,³ where a noncompliant but nonstrictured anas-

tomosis might significantly contribute to defecation difficulty in a small proportion of patients.⁴ Some of the risks associated with CSH following a complete circumferential resection may be technically obviated by refinements in the devices used and by technical modifications of the procedure.

On the other hand, most of prolapsing hemorrhoids are not circumferential but segmental,^{5,6} with the most common location being in the right anterior, right posterior, and left lateral positions (Fig. 1). Therefore, we propose and outline a modified technique of segmental stapled hemorrhoidopexy developed in our unit that may overcome some of the inherent limitations and problems encountered with CSH. Previous publications by our group of the preliminary outcomes of this procedure, which we have called the tissue-selecting technique (TST), show that it is a safe and effective technique for the management of prolapsing hemorrhoids without any significant risk either of anal stricture or of RVF development.^{4,7} According to a recent national survey, almost 60,000 TST procedures have been performed since the introduction of this technique in 2008; TST has become the preferred procedure for the management of prolapsing hemorrhoids in many tertiary referral institutions throughout China (H.-C. Lin, unpublished data, 2012). This technical note describes the operative details of the method, highlighting some important technical issues.

OPERATIVE TECHNIQUE

Preparation and Instrumentation

All patients are given a bowel-cleansing enema before surgery and prophylactic antibiotics. The TST procedure is performed by using a specialized TST kit (Touchstone, Suzhou, China) consisting of a stapler, a biwindow (or sometimes a triwindow) anoscope (Fig. 2), and an obturator that can be inserted into the anoscope. With these specially designed anoscopes, TST was developed to perform a segmental stapled hemorrhoidopexy in

Supplemental digital content is available for this article. Direct URL citations appear in the printed text, and links to the digital files are provided in the HTML and PDF versions of this article on the journal's Web site (www.dcrjournal.com)

Disclosure: None reported

Correspondence: Dong-Lin Ren, M.D., Department of Coloproctology, the Sixth Affiliated Hospital of Sun Yat-sen University (Gastrointestinal & Anal Hospital), 26 Yuancun Er Heng Rd, Guangzhou 510655, People's Republic of China. E-mail: rendl111@163.com

Dis Colon Rectum 2013; 56: 1320–1324

DOI: 10.1097/DCR.0b013e3182a4aca5

© The ASCRS 2013

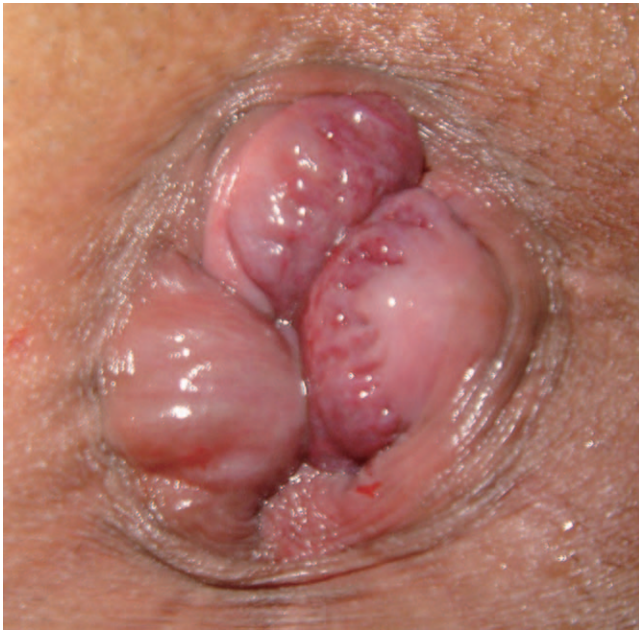

FIGURE 1. Most of prolapsing hemorrhoids are typically 3 major displacement anal cushions, located in the right anterior, right posterior, and left lateral aspect of the anal canal.

comparison with CSH. The TST stapler deploys 2 staggered rows of titanium staples 33 mm in diameter. The staple length is 3.8 mm before closure with a height of approximately 1.5 mm when the instrument is closed. The specially designed anoscope includes a hollow body with 2 or 3 apertures that is closed at the distal end with a small opening located at the top.

Anesthesia

A combined spinal-epidural anesthesia is preferred in our unit because it provides sufficient relaxation of the anal sphincter muscles and allows easy insertion of the anoscope.




FIGURE 2. A, Biwindow anoscope with an obturator. B, Triwindow anoscope. The red dot-line box indicates the window of the anoscope, and the yellow arrows indicate the plastic bridge between the windows.

Patient Positioning

The patient is placed in a prone jackknife position that provides optimal exposure of the anorectal lumen and permits ready and comfortable access for both the surgeon and the assistant. Because of the dependent drainage of the hemorrhoidal venous complex, the prolapsing hemorrhoids tend to be less congested, resulting in reduced blood loss during the procedure. By contrast, in selected patients with significant cardiac or pulmonary dysfunction, we prefer to use either the lithotomy or left lateral position.

Insertion of the Anoscope

The procedure is commenced with repeated gentle anal dilation with the use of a lubricated obturator. Following this, an anoscope is inserted together with the obturator, advancing through the anal canal first anteriorly, and then posteriorly, keeping in mind the direction of the anorectal junction. The anoscope is adjusted until its window is aligned with the mucosa above the prolapsing hemorrhoids. In general, the triwindow anoscope is used when the hemorrhoids are classically disposed in the right anterior, right posterior, and left lateral locales, whereas the biwindow anoscope is used when the hemorrhoidal positions are atypically disposed or circumferential in nature. It should be noted that the width of the aperture in the biwindow anoscope is slightly greater than the width of the aperture in the triwindow anoscope. For female patients, the plastic bridge between the 2 windows is deliberately

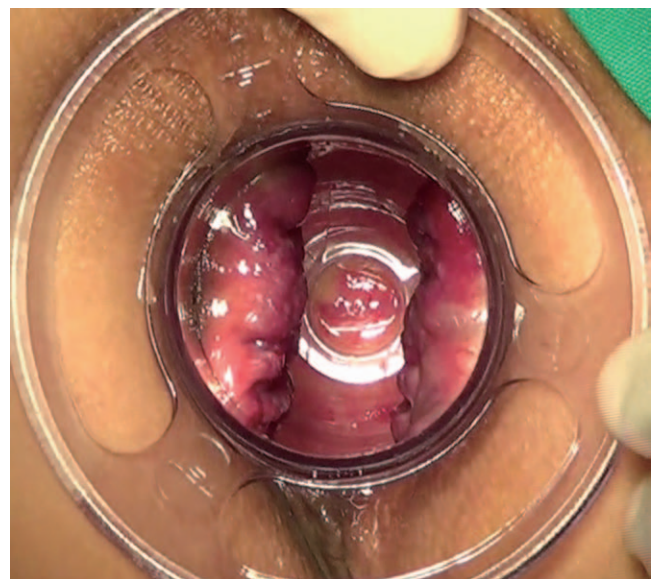


FIGURE 3. For the female patients, the bridge between the 2 windows is placed against the rectovaginal septum. After withdrawal of the obturator, the prolapsing mucosa above is pushed back, and only the rectal tissue intended for removal protrudes through the windows of the anoscope.

placed against the rectovaginal septum for protection (Fig. 3). After withdrawal of the obturator, the prolapsing mucosa above is pushed back so that only the tissue intended for removal protrudes through the windows of the anoscope.

Placement of Pursestring Suture and Insertion of the Stapler

The transparent anoscope provides an easy visualization of the dentate line, allowing the surgeon to check the correct position of the placement of pursestring. At this time, a 2/0 Vicryl suture (Ethicon, Cincinnati, OH) is placed approximately 3 cm above the dentate line, and the needle only catches the mucosa and/or submucosa that protrude through the window (Fig. 4). Because of the bridge between the windows, the pursestring is only segmental rather than circumferential as in a conventional CSH. To slightly rotate the anoscope, the rectal mucosa can be maximally caught and pulled through the windows of the anoscope by the segmental pursestring. The stapler is then opened, and the anvil is introduced and positioned above the pursestring suture (which is secured to the rod), where segments of rectal tissue (2 or 3) are pulled into the stapler housing by the traction suture to form several fan-shaped mucosal flaps (Fig. 5).

Management of Mucosal Bridge and "Dog Ears"

After the stapler is fired and then removed, a minimal mucosal bridge with some staples connecting the 2 edges of the mucosectomies is formed similarly to the stapled transanal rectal resection procedure (Fig. 6). These bridges are separated with scissors. The free ends of the dis-

sected mucosal bridges form "dog ears" (Fig. 7), which are separately ligated. Circumferential inspection of the anorectal lumen is then performed where occasional bleeding, which may be controlled with an absorbable suture, is observed along the stapled line. The stapler is checked to confirm that the 2 or 3 rectal tissue segments have been removed. In some circumstances in which the hemorrhoids do not completely disappear after TST and residual skin tags remain, minimal excision of these skin tags is also performed.

Highlights of the TST

The TST is specifically designed to treat segmental prolapsing hemorrhoids through segmental stapled hemorrhoidopexy rather than CSH. It is encouraging that TST has potential to overcome the shortcomings of a CSH (associated with more stricture, RVF, and adverse function) with the inherent merit of a CSH (easy to perform, shorter operative time, less bleeding, and higher consistency among surgeons) in comparison with traditional nonstapling hemorrhoidectomy. Because of the protection by the bridge of the anoscope, the normal rectal wall is preserved between the mucosectomies with the expectation that normal rectal compliance is maintained, potentially resulting in improved functional outcome. Furthermore, because TST spares the tissue between mucosectomies, it protects tissue adjacent to the rectovaginal septum in women, resulting in a reduced risk for RVF formation and for the development of postoperative anal stricture, as well.

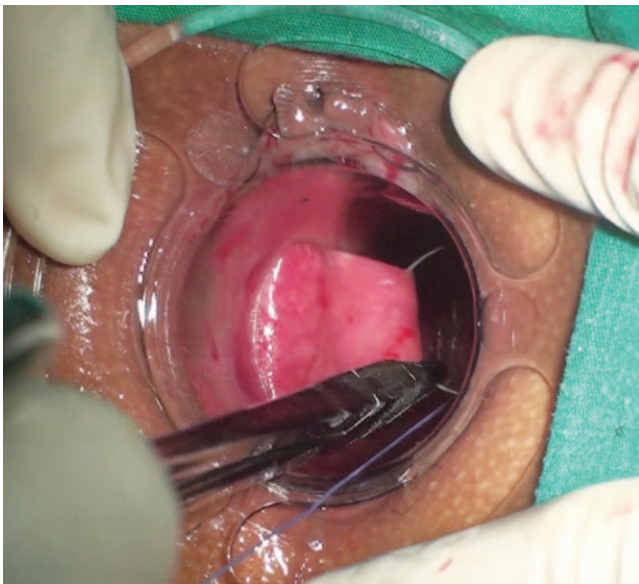

FIGURE 4. Placement of the segmental pursestring through the triwindow anoscope.

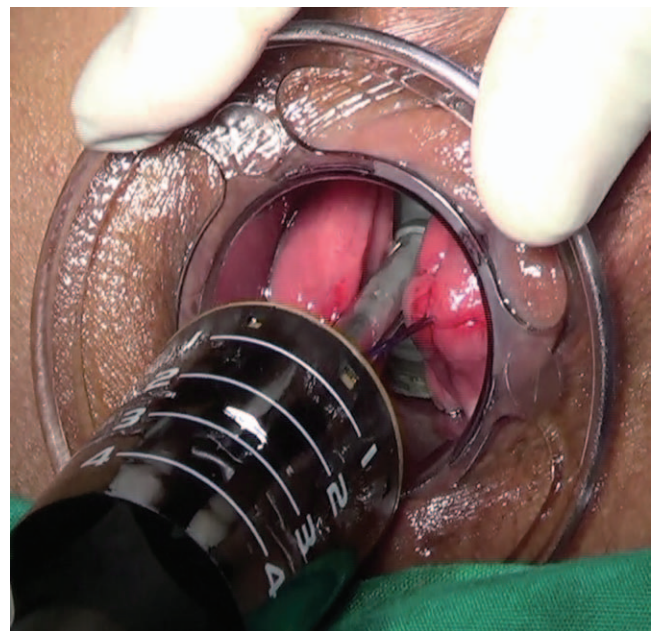

FIGURE 5. A representative image illustrating a segmental stapled hemorrhoidopexy for prolapsing hemorrhoids. Fan-shaped (2 pieces) flaps were drawn into the stapled device.

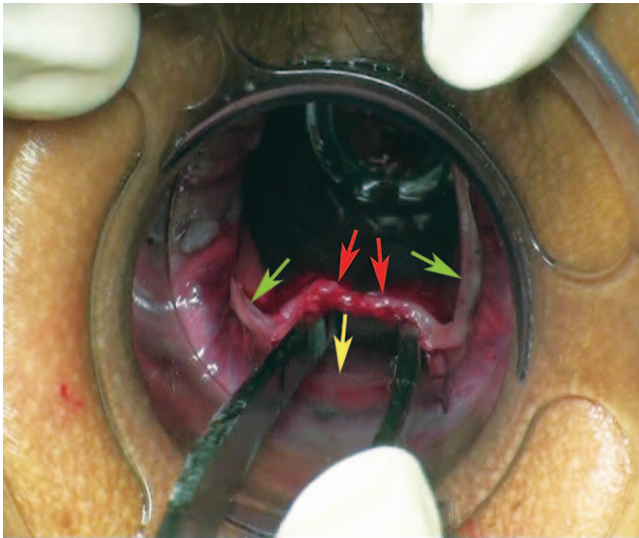


FIGURE 6. A minimal mucosal bridge (the red arrow) with some staples connecting the 2 edges of the mucosectomies (akin to the stapled transanal rectal resection procedure) is separated. The green arrows indicate the stapled line. The yellow arrow indicates the mucosal bridge (normal rectal mucosa) between the mucosectomies.

DISCUSSION

The TST was originally designed to treat segmental prolapsing hemorrhoids, coupling the advantages of a CSH with a more minimalist approach designed to reduce the likelihood of some of the inherent complications of the conventional CSH procedure, such as an anal stricture or a RVE. Our preliminary clinical nonrandomized case-cohort studies have shown that the 2-year recurrence rate is 2.9% with TST and

5.3% with CSH; TST has less postoperative pain and fewer episodes of urgency, and it has not been associated with any cases of postoperative anal incontinence or stricture formation.⁴ These encouraging results suggest a value in conducting a prospective, multicenter, randomized controlled trial comparing TST with the CSH procedure in patients for prolapsing symptomatic hemorrhoids. At present, we feel that TST is contraindicated in patients with severe proctitis, anismus, enterocele, or significant anal stenosis.

One advantage of the TST procedure is the negligible risk of an anal stricture. With a circular anastomosis, an anal stricture following the CSH procedure has been reported in between 0.8% and 22% of cases.^{3,8} In some of these patients, injudicious and excessive removal of part of the anoderm may have contributed; however, even with a meticulous technique, there remains a small but significant risk of an anal canal stricture with any method using circumferential mucosal excision. Equally, a circular mucosectomy has a greater chance of resulting in a RVE, particularly in parturient women with an attenuated rectovaginal septum. The new TST technique prevents both of these complications by exploiting the bridge as part of the design of the specially designed anoscope.

In our clinical practice, we have noted that some patients report difficulty in defecation after a few postoperative months where an anal stricture was excluded by digital rectal examination. In this respect, it is likely that this represents a disturbance in rectal compliance where rectal distensibility and sensory thresholds decrease following CSH.^{9,10} It is suggested that the presence of a fixed, noncompliant circular staple ring will contribute to fecal urgency in some patients and leakage where our limited experience has shown clinical improvement following longitudinal scar excision. The concept of partial resections designed to preserve some normal rectal bridging tissue is aimed at safeguarding rectal compliance and functional outcome.

ACKNOWLEDGMENT

The authors thank Prof Andrew Zbar for his critical review of the manuscript.

REFERENCES

1. Ommer A, Hinrichs J, Möllenberg H, Marla B, Walz MK. Long-term results after stapled hemorrhoidopexy: a prospective study with a 6-year follow-up. *Dis Colon Rectum*. 2011;54:601–608.
2. Tjandra JJ, Chan MK. Systematic review on the procedure for prolapse and hemorrhoids (stapled hemorrhoidopexy). *Dis Colon Rectum*. 2007;50:878–892.
3. Au-Yong I, Rowsell M, Hemingway DM. Randomised controlled clinical trial of stapled haemorrhoidectomy vs conventional haemorrhoidectomy; a three and a half year follow up. *Colorectal Dis*. 2004;6:37–38.

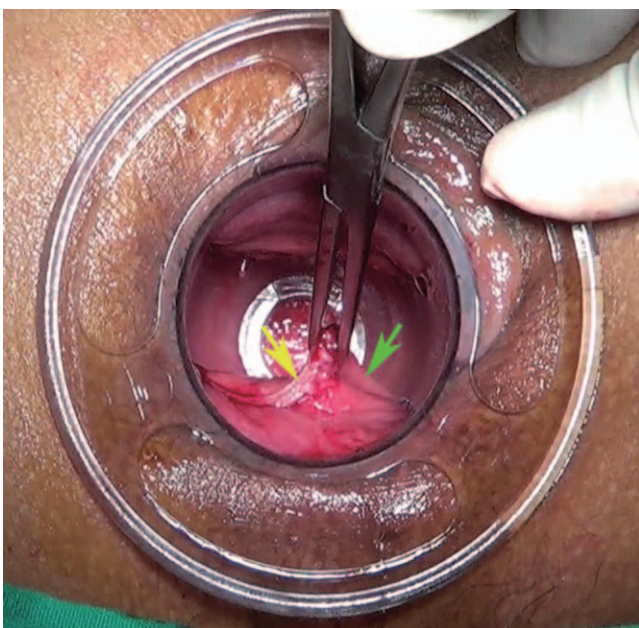

FIGURE 7. Free end of the dissected mucosal bridge forming a “dog ear.” The yellow arrow indicates the stapled line. The green arrow represents normal tissue.

4. Lin HC, Ren DL, He QL, et al. Partial stapled hemorrhoidopexy versus circular stapled hemorrhoidopexy for grade III-IV prolapsing hemorrhoids: a two-year prospective controlled study. *Tech Coloproctol.* 2012;16:337–343.
5. Varut L. Hemorrhoids: From basic pathophysiology to clinical management. *World J Gastroenterol.* 2012; 18: 2009–2017.
6. Thomson WH. The nature of haemorrhoids. *Br J Surg.* 1975;62:542–552.
7. Lin HC, He QL, Ren DL, et al. Partial stapled hemorrhoidopexy: a minimally invasive technique for hemorrhoids. *Surg Today.* 2012;42:868–875.
8. Brisinda G, Vanella S, Cadeddu F, et al. Surgical treatment of anal stenosis. *World J Gastroenterol.* 2009;15:1921–1928.
9. Corsetti M, De Nardi P, Di Pietro S, Passaretti S, Testoni PA, Staudacher C. Rectal distensibility and symptoms after stapled and Milligan-Morgan operation for hemorrhoids. *J Gastrointest Surg.* 2009;13:2245–2251.
10. Ren DL, Lin HC. Reply to comment on “partial stapled hemorrhoidopexy versus circular stapled hemorrhoidopexy for grade III-IV prolapsing hemorrhoids: a two-year prospective controlled study”. *Tech Coloproctol.* 2012; 16:347–348.